

A 50% decrease of serum calcitonin concentrations within 30 minutes after surgery indicates that all the calcitonin-producing tumor tissue has been removed, whereas a calcitonin decline <50% suggests persistent residual tumor

Faggiano A, Milone F, Ramundo V, Chiofalo MG, Ventre I, Giannattasio R, Severino R, Lombardi G, Colao A, Pezzullo L. A decrease of calcitonin serum concentrations less than 50 percent 30 minutes after thyroid surgery suggests incomplete C-cell tumor tissue removal. *J Clin Endocrinol Metab* 2010. 0-0045 [pjc.2011ii];10.1210/jc.2010-0045[doi]

SUMMARY

BACKGROUND

The prognosis of medullary thyroid carcinoma (MTC) depends greatly on the completeness of the first surgical treatment. However, whether central lymph-node compartment dissection should be performed with total thyroidectomy is a matter of debate unless there is preoperative or intraoperative evidence revealing the presence of lymph-node metastases. Without this information, there is relatively little information that can indicate to the surgeon whether the tumor has been completely removed after total thyroidectomy. The aim of this study was to evaluate the reliability of intraoperative calcitonin as an effective predictor of residual tumor and the final outcome of surgery in patients with MTC.

PATIENTS AND METHODS

Patients

The study subjects comprise 20 patients, 9 men and 11 women, 25 to 70 years of age (mean (\pm SD) 50 ± 2.3), who were candidates for thyroid surgery on the basis of abnormally elevated serum calcitonin levels, without preoperative evidence of lymph-node metastases or distant metastases. All of the patients had thyroid surgery on the basis of elevated basal calcitonin levels or pentagastrin (PG)-stimulated calcitonin levels above 100 ng/L. Five patients had basal serum calcitonin concentrations above 100 ng/L, and 15 others had basal calcitonin concentrations ranging from 18 to 68 ng/L that increased to over 100 ng/L with PG stimulation.

Neck ultrasonography identified thyroid nodules on all of the patients; 8 patients had a single nodule and 12 had two or more nodules, but none had lymph-node metastases identified on the preoperative ultrasound. Ultrasound-guided fine-needle aspiration biopsy was performed on thyroid nodules with features suspicious for malignancy. None of the patients tested positive for a RET mutation.

All patients had total thyroidectomy and central compartment lymph-node dissection with removal of bilateral pretracheal and paratracheal compartments. As none of the patients had lymph-node metastases on the preoperative ultrasound examination or the intraoperative surgical exploration, an extensive neck dissection comprising both central and bilateral cervical lymph-node dissection was not performed in any patient. MTC was found on the histologic examination in 10 patients, and 10 others had C-cell hyperplasia.

Outcome

After surgery, calcitonin was measured every 3 months, and then was measured every 6 months. A PG test was performed 6 months after surgery in patients with a histologic diagnosis of MTC. Mean follow-up after surgery was 14.6 ± 1.7 months (range, 6 to 30). In 16 of the 20 patients, there was no evidence of persistent disease or relapse, and 4 patients had persistent disease, 2 of whom had both basal and PG-stimulated abnormally high calcitonin levels, and 2 others had basal calcitonin levels of 5 ng/L or less, with a progressive increase of calcitonin during follow-up and a positive PG-stimulated calcitonin level. This group of patients had a radiologic workup and periodic ultrasound follow-up with Doppler, contrast-enhanced computed tomography and magnetic resonance imaging, and ^{18}F -deoxy-d-glucose positron-emission tomography. One of the four patients with persistent disease after surgery had ultrasound evidence of tumor remnant in the neck lymph nodes. The other 3 patients with elevated postoperative calcitonin levels did not have signs of tumor at the last radiologic examination, 12, 16, or 22 months after surgery.

Calcitonin Assay

Serum calcitonin was determined by a commercially available two-site immunometric assay with normal values of 0.4 to 18.9 ng/L and an analytic sensitivity of 1 ng/L or less. No hook effect was observed until a calcitonin concentration increased to 500,000 ng/L. A PG-plus-calcium test was performed as follows: calcium was first injected intravenously in 1 minute at a dose of 2 $\mu\text{g}/\text{kg}$ of body weight. PG was injected in 15 seconds at a dose of 0.5 $\mu\text{g}/\text{kg}$ in 5 ml of NaCl solution 0.9%. Blood samples were collected at 0, 1, 2, 3, 5, and 10 minutes after the injection, and the assay run time was 15 minutes. According to Costante et al. (1), the calcitonin peak greater than 100 pg/ml after a PG test is considered as positive for MTC.

RESULTS

The Outcome of Patients Who Had Surgery and Calcitonin Measurement at 10 Minutes and 30 Minutes after Surgery (Figures 1 and 2)

Histologic examination identified 10 patients with MTC and 10 with C-cell hyperplasia. Among patients with MTC, the tumor stage was T1N0 in six, T2N0 in two, and T2N1 in two (Figure 1). Among the entire patient population, preexcision serum calcitonin values were 908 ± 695 ng/L (range, 11 to 9160) and postexcision values were 319 ± 202 ng/L (range, 9 to 2845) at 10 minutes after the surgical excision and 146 ± 75 ng/L (range, 7 to 10656) at 30 minutes after the surgical excision. The mean

calcitonin decrease was $44 \pm 4.6\%$ (range, 13 to 76) 10 minutes after surgery and $61 \pm 2.9\%$ (range, 39 to 80) 30 minutes after surgery (Figure 2).

A receiver operating characteristic curve identified a decrease of serum calcitonin concentrations greater than 50% at 30 minutes after surgery, which was able to significantly distinguish with 100% sensitivity and specificity between patients who were cured and those who had disease persistence during the follow-up ($P < 0.005$) (Figure 2). No statistical significance was found in predicting the patient outcome when considering calcitonin concentrations at 10 minutes after surgery. However, an intraoperative calcitonin decrease greater than 50% at 30 minutes after surgery was achieved in all 16 patients who had

complete remission during follow-up ($66 \pm 2.4\%$), whereas the calcitonin decrease at 30 minutes after surgery was 16, 39, 40, and 44% in the four patients, who had persistent disease after surgery, as compared with patients who had a 50% or more decline in calcitonin in patients who were free of MTC (Figure 2).

Conclusion

The main finding in this study is that an intraoperative calcitonin that decreases 50% or more 10 minutes after surgery is a reliable indicator that a patient with MTC is free of disease after surgery limited to total thyroidectomy and central compartment lymph-node dissection, whereas a calcitonin 30 minutes after surgery that fails to decline 50% or more suggests that the surgeon should extend the operation to other lymph-node compartments.

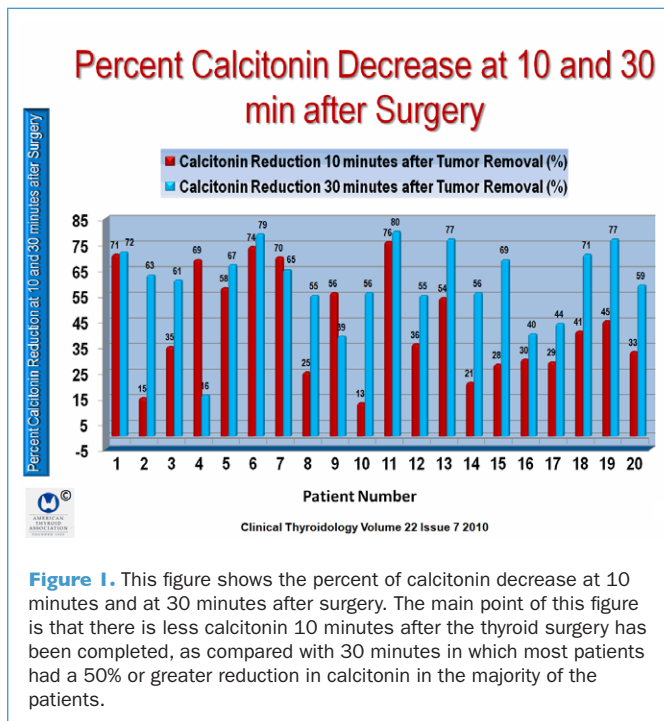
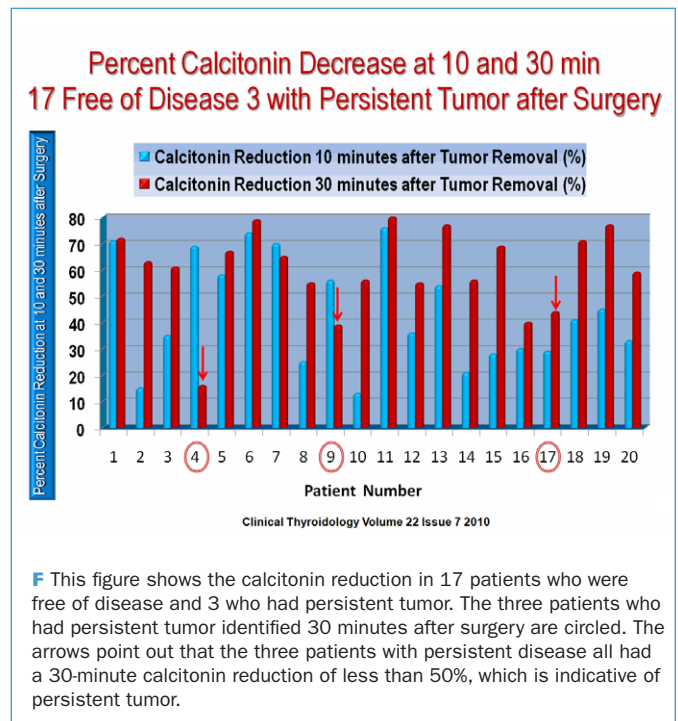


Figure I. This figure shows the percent of calcitonin decrease at 10 minutes and at 30 minutes after surgery. The main point of this figure is that there is less calcitonin 10 minutes after the thyroid surgery has been completed, as compared with 30 minutes in which most patients had a 50% or greater reduction in calcitonin in the majority of the patients.



F This figure shows the calcitonin reduction in 17 patients who were free of disease and 3 who had persistent tumor. The three patients who had persistent tumor identified 30 minutes after surgery are circled. The arrows point out that the three patients with persistent disease all had a 30-minute calcitonin reduction of less than 50%, which is indicative of persistent tumor.

COMMENTARY

MTC is a tumor with a 10-year relative survival rate of 75%, which is approximately fourfold that of papillary thyroid cancer, underscoring the gravity of this disease (2). Surgery is the mainstay of therapy for the initial treatment. If the primary surgery is incomplete, the initial treatment is ineffective in achieving disease remission (3). Although preoperative calcitonin concentrations have been reported to predict the postoperative calcitonin levels of patients with MTC (1), no clinical parameters clearly predict the postoperative outcome of patients with this disease (3).

The study by Faggiano et al. demonstrates that intraoperative monitoring of calcitonin 10 minutes after surgery is a reliable way to determine whether a patient can be considered free of disease after surgery. The authors suggest that intraoperative calcitonin monitoring seems to be more cost-effective than intraoperative PG testing in the recognition of patients with incomplete surgery. The study shows that the main difference

is that the sensitivity and negative predictive value of the intraoperative calcitonin monitoring was 100% with no false negative results, whereas the sensitivity of intraoperative PG testing was 80% and had a negative predictive value of 91%, meaning that PG testing did not recognize 20% of the patients who had persistent disease after surgery.

The results of this study clearly demonstrate that a decrease of calcitonin serum concentrations greater than 50% 30 minutes after surgery indicates that all the calcitonin-producing tumor tissues have been removed, while a calcitonin decrease of less than 50% suggests that an incomplete surgery has been performed, giving the surgeon an opportunity to perform another lymph-node compartment dissection.

This is an important study that should be read in its entirety to obtain its full impact.

— Ernest L. Mazzaferri, MD, MACP

References

1. Costante G, Meringolo D, Durante C, et al. Predictive value of serum calcitonin levels for preoperative diagnosis of medullary thyroid carcinoma in a cohort of 5817 consecutive patients with thyroid nodules. *J Clin Endocrinol Metab* 2007;92:450-5.
2. Hundahl SA, Fleming ID, Fremgen AM, et al. A National Cancer Data Base report on 53,856 cases of thyroid carcinoma treated in the U.S., 1985-1995. *Cancer* 1998;83:2638-48.
3. Wells SA Jr, Baylin SB, Leight GS, et al. The importance of early diagnosis in patients with hereditary medullary thyroid carcinoma. *Ann Surg* 1982;195:595-9.

American Thyroid Association

Prevent
Diagnose
Treat

www.thyroid.org

Support valuable patient education
and crucial thyroid research!