

# Ultrasound-guided fine-needle aspiration biopsy of thyroid nodules in children and adolescents has high diagnostic accuracy

Izquierdo R, Shankar R, Kort K, Khurana K. Ultrasound-guided fine-needle aspiration in the management of thyroid nodules in children and adolescents. *Thyroid* 2009;19:703-5.

## SUMMARY

**BACKGROUND** The incidence of thyroid nodules in children and adolescents ranges from 1% to 2%. The aim of this study was to assess the diagnostic accuracy, sensitivity, and specificity of ultrasound-guided fine-needle aspiration biopsy (US-FNAB) in children and adolescents with thyroid nodules.

**METHODS** This is a retrospective analysis of the efficacy of US-FNAB in 42 children and adolescents in whom 52 thyroid nodules were identified. US-FNAB was performed with a 25-gauge needle attached to a 10-ml syringe. Up to four needle passes were performed per nodule and two slides were made from each aspiration for all nodules >1 cm. The cytology specimens were air-dried and stained with Diff-Quick or fixed immediately in 95% ethanol and stained by the Papanicolaou method. All thyroid examinations and US-FNAB studies were performed in a similar manner by one endocrinologist. The cytology and histopathology diagnoses were compared in all patients who had thyroid surgery. The diagnostic accuracy, sensitivity, and specificity were calculated from the results from each nodule. A cytology diagnosis of indeterminate or malignant was considered positive, a nonneoplastic result was considered negative, and a nodule confirmed as benign on the histopathology specimen was defined as true negative. Cytology specimens that were inadequate for diagnosis were not included in the calculations of accuracy.

**RESULTS** A total of 52 nodules in 42 patients underwent US-FNAB. The mean age of the patients was 14.75 years (range, 8.67 to 19.75); 29 patients (69%) were female, and 13 (31%) were male. The surgical histology results were available in 16 thyroid nodules. The US-FNAB cytology specimens were papillary thyroid cancer in 6 nodules (12%), indeterminate in 2 (4%), nonneoplastic in 42 (83%), and inadequate for diagnosis in 1 (2%) (Figure 1). Twenty-two of 36 nodules with benign cytology (61%) had follow-up with clinical and ultrasound examinations for an average of 20 months without any significant change in nodule size. Among the 16 patients who had thyroid surgery for which the histology diagnosis was available, the US-FNAB sensitivity was 100% and the specificity was 89%. There were no known false-negative cytology specimens, but there was one false-positive case. The overall diagnostic accuracy was 94%, which compares favorably with the results in a previous publication by these authors of historical controls that had fine-needle aspiration biopsy by palpation (Figure 2).

**CONCLUSION** Ultrasound-guided fine-needle aspiration biopsy of thyroid nodules in children and adolescents has high diagnostic accuracy.

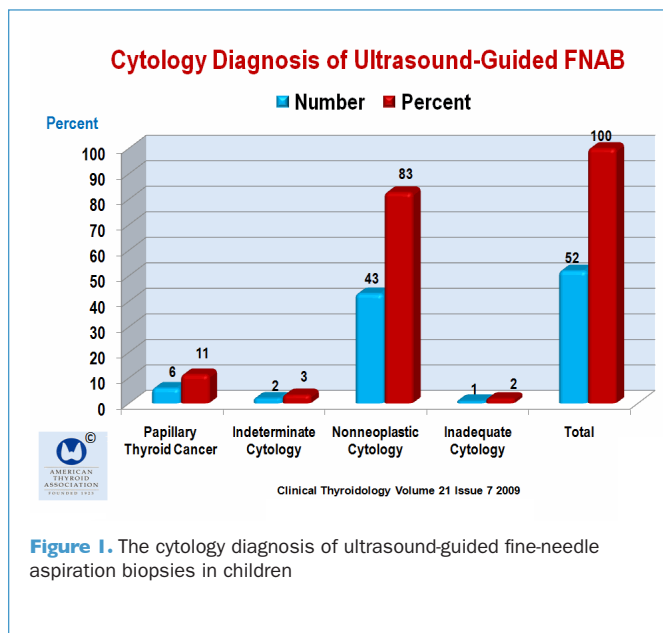


Figure 1. The cytology diagnosis of ultrasound-guided fine-needle aspiration biopsies in children

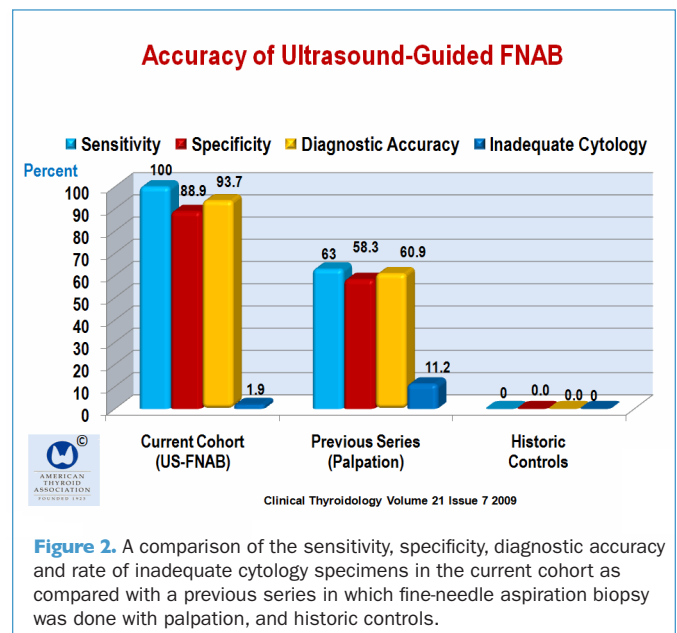


Figure 2. A comparison of the sensitivity, specificity, diagnostic accuracy and rate of inadequate cytology specimens in the current cohort as compared with a previous series in which fine-needle aspiration biopsy was done with palpation, and historic controls.

**COMMENTARY**

A number of studies show that US-FNAB is more precise and provides greater diagnostic accuracy than does FNAB performed by palpation to guide placement of the aspiration needle. Danese et al. (1) found that the sensitivity, specificity, and diagnostic accuracy was 92% vs. 97%, 69% vs. 70%, and 73% vs. 76%. In another study, by Carmeci et al. (2). The cancer yield at surgery for palpation-FNAB was 40%, and the cancer yield at surgery for US-FNAB was 59%. A study by Redman et al. (3) concluded that US-FNAB with on-site evaluation of cytology specimens substantially increases the adequacy of cytology specimens and decreases the number of required needle passes, which ultimately reduces patient discomfort and diagnostic errors, thus raising the question as to whether this should eventually become the standard of care. I think this is a goal that training programs should strive to achieve.

The study by Izquierdo et al. shows that the advantage of ultrasound guidance for FNAB extends to children, although the study is limited by the small number of patients and the lack of

a contemporary control group. Still, the findings are in line with more robust studies in adults.

The current American Thyroid Association management guidelines for patients with thyroid nodules and differentiated thyroid cancer (4) makes the following recommendations concerning neck ultrasound in the workup of thyroid nodules: Ultrasound guidance for FNAB is recommended for those nodules that are nonpalpable, predominantly cystic, or located posteriorly in the thyroid lobe. Recommendation B

R6a Ultrasound guidance should be used when repeating the FNAB procedure for a nodule with an initial nondiagnostic cytology result. Recommendation A

My opinion is that most thyroid nodules that require fine-needle aspiration biopsy should be performed under ultrasound guidance and with assessment for cytology adequacy.

**Ernest L. Mazzaferri, MD, MACP**

**References**

1. Danese D, Sciacchitano S, Farsetti A, et al. Diagnostic accuracy of conventional versus sonography-guided fine-needle aspiration biopsy of thyroid nodules. *Thyroid* 1998;8:15-21.
2. Carmeci C, Jeffrey RB, McDougall IR, et al. Ultrasound-guided fine-needle aspiration biopsy of thyroid masses. *Thyroid* 1998;8:283-9.

3. Redman R, Zalaznick H, Mazzaferri EL, et al. The impact of assessing specimen adequacy and number of needle passes for fine-needle aspiration biopsy of thyroid nodules. *Thyroid* 2006;16:55-60.
4. Cooper DS, Doherty GM, Haugen BR, et al. Management guidelines for patients with thyroid nodules and differentiated thyroid cancer. *Thyroid* 2006;16:109-42.

**14<sup>th</sup> INTERNATIONAL THYROID CONGRESS**

**September 11–16, 2010 • Paris, France**

**E-mail: [itc2010@mci-group.com](mailto:itc2010@mci-group.com)**

**Website: [www.itc2010.com](http://www.itc2010.com)**