

There is a high rate of tumor multifocality and lymph-node metastases in papillary thyroid cancers that arise in a thyroglossal duct cyst, including a relatively high rate of “skip” metastases

Hartl DM, Al Ghuzlam A, Chami L, Leboulleux S, Schlumberger M, Travagli JP. High rate of multifocality and occult lymph node metastases in papillary thyroid carcinoma arising in thyroglossal duct cysts. *Ann Surg Oncol* 2009;16:2595-601.

SUMMARY

BACKGROUND

Thyroglossal-duct cyst carcinoma (TDC) is uncommon, and its management remains controversial. The object of this study was to examine the rate of tumor multifocality, lymph-node metastases, and long-term results with TDC.

METHODS

Records from 1979 through 2008 were reviewed for cases of differentiated thyroid cancer in a TDC discovered during a Sistrunk procedure, on preoperative cytology, or on frozen-section diagnosis. Data were collected on patient demographics, tumor size and stage, thyroid tumor multifocality, lymph-node metastases, radioiodine (¹³¹I) therapy, and follow-up with neck ultrasound and thyroglobulin (Tg) levels.

RESULTS

Patient Demographics and Initial Presentation (Figure 1)

The study subjects were 18 patients, 13 women (72%) and 5 men (28%), with an average age of 41.5 years (range, 15 to 68) who were treated for papillary thyroid TDC (Figure 1). Five patients were initially treated at the authors' institution, and 13 were referred from other hospitals after the diagnosis of TDC had been established. Only one patient had a history of thyroid disease with ¹³¹I treatment for Graves' disease 1 year prior to the diagnosis of TDC. Another patient had a history of external-beam pelvic radiation at age 34 for a testicular seminoma, 13 years before the diagnosis of TDC, which at the

time of this study was in complete remission. For 17 patients, the initial presentation of the problem was that of a typical TDC that appeared from several months to years before surgery with no clinical signs of malignancy. Another patient who had TDC diagnosed during pregnancy had TDC surgery after delivery. Preoperative ultrasonography was performed in all patients but only two had thyroid abnormalities. One had two 5-mm right-lobe thyroid nodules and the other had one 25-mm nodule in the right thyroid lobe and two 5-mm nodules in the left lobe. The tumors in the left thyroid lobe were 4 to 27 mm (average, 15.2). Four patients treated at the authors' hospital had fine-needle aspiration biopsy (FNAB). The cytology was insufficient in 1 patient, suspicious in 2 patients, and malignant in 1 patient.

The Initial Surgery and the Extent of Malignancy (Figures 2 to 5)

Total thyroidectomy was performed in 15 of the 18 patients (83%) as a secondary procedure to the Sistrunk procedure (Figure 2). Further surgical procedures were isthmusectomy in addition to the Sistrunk procedure in 1 patient, and Sistrunk procedure alone in 2 patients and central neck dissection with or without lateral compartment dissection in 16 patients (89%) (Figure 3). Other tumor foci were found in the thyroid lobes in 9 of 16 patients (56%), 15 of whom had thyroidectomy (83%) and 1 isthmusectomy. In addition to the TDC, three patients had 1- to 2-mm tumors in both thyroid lobes. Lymph-node metastases were found in 12 of 16 patients (75%) who had prophylactic neck dissection. Lymph-node metastases were found in 6 of 15 (40%) of the central (level VI) neck-compartment dissections, and in 9 of 15 lateral neck

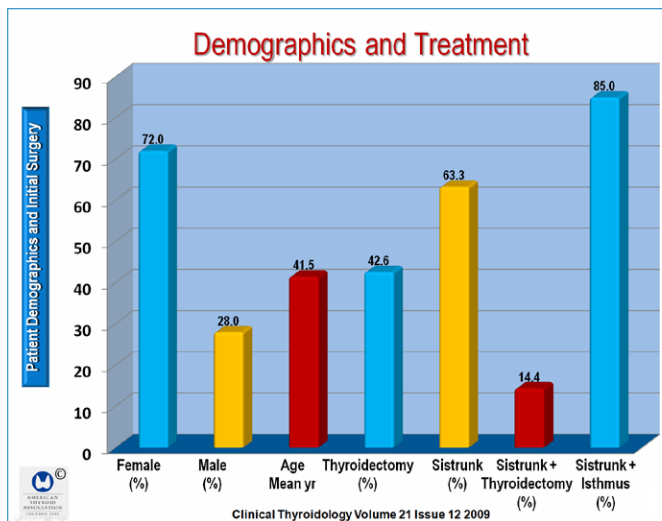


Figure 1. This figure shows the demographic characteristics in the 18 patients in this study, and the percent of patients who had Sistrunk procedures either alone, or with total thyroidectomy, or thyroid isthmusectomy

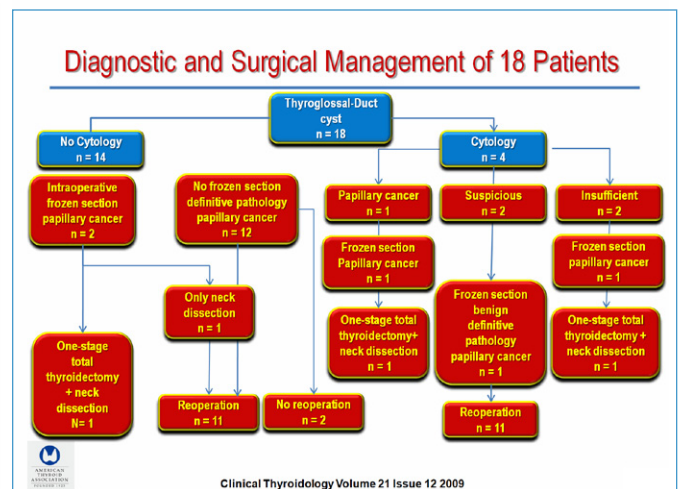


Figure 2. This figure shows the diagnostic and surgical management of the 18 patients who had papillary thyroid carcinoma in a thyroglossal duct remnant. Only four of the patients had FNA cytology, and the diagnosis of cancer was made on frozen section studies, reoperation and one-stage total thyroidectomy.

dissections (60%). The lateral neck metastases were bilateral in 4 patients (22%), on the left side only in 3 (5%), and on the right side only in 2 (13%). “Skip” metastases were found in lateral levels III and IV without central compartment metastases in 6 of 15 patients

(40%). Level II (subdiaphragic) lymph nodes were found in 2 patients, 1 of whom had only level II lymph-node metastases. Of the 12 of 18 patients (67%) with lymph-node metastases, 6 (50%) had tumor foci in the thyroid whereas the other 6 had no tumor foci (Figure 4).

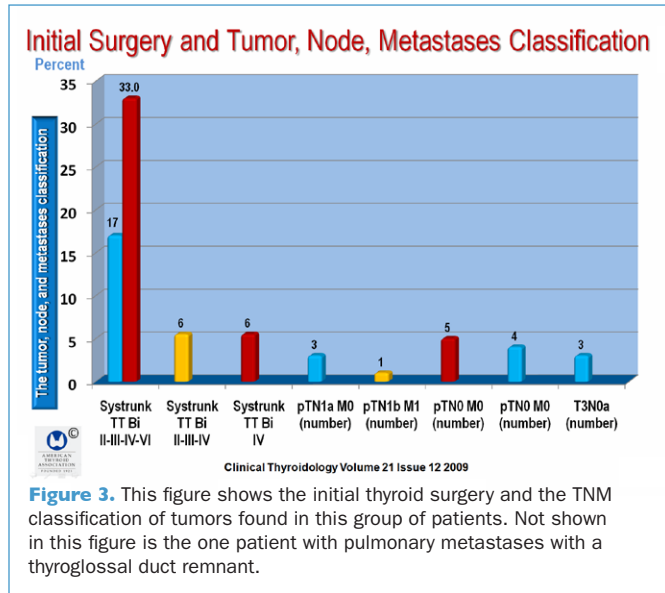


Figure 3. This figure shows the initial thyroid surgery and the TNM classification of tumors found in this group of patients. Not shown in this figure is the one patient with pulmonary metastases with a thyroglossal duct remnant.

The tumor stage was pT1 in 15 patients (83%), pT3 in 3 (17%), pN0 in 4 (22%), PN1a in 3 (17%), and PN1b in 9 (50%), M0 in 17 (94%) and M1 in 1 patient (6%). Nine of the T1N0 tumors were upgraded to N1a or N1b after prophylactic neck dissection. Twelve patients (67%) were treated with 100 mCi or more of ¹³¹I. Eight of 18 (44%) received 100 mCi because of lymph-node metastases and 11 (92%) had multifocal tumors with or without lymph-node metastases (Figure 3).

After a mean follow-up of 11 years (median, 12), no patient was lost to follow-up and none had evidence of disease, including neck ultrasonography and thyrotropin-stimulated thyroglobulin levels of <1 µg/L in 11 patients and 2 µg/L in 2 patients. None of the patients had permanent recurrent laryngeal-nerve paralysis or hypoparathyroidism.

CONCLUSION

There is a high rate of tumor multifocality and lymph-node metastases in papillary thyroid cancers that arise in a thyroglossal duct, including a relatively high rate of skip metastases.

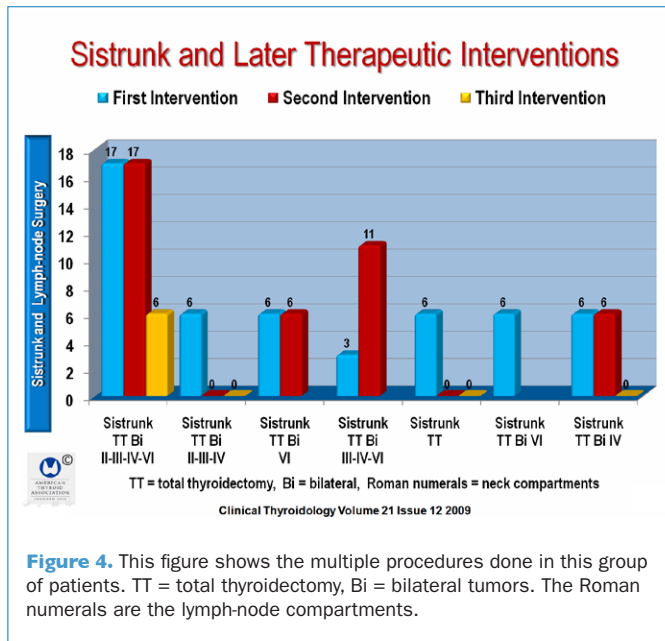


Figure 4. This figure shows the multiple procedures done in this group of patients. TT = total thyroidectomy, Bi = bilateral tumors. The Roman numerals are the lymph-node compartments.

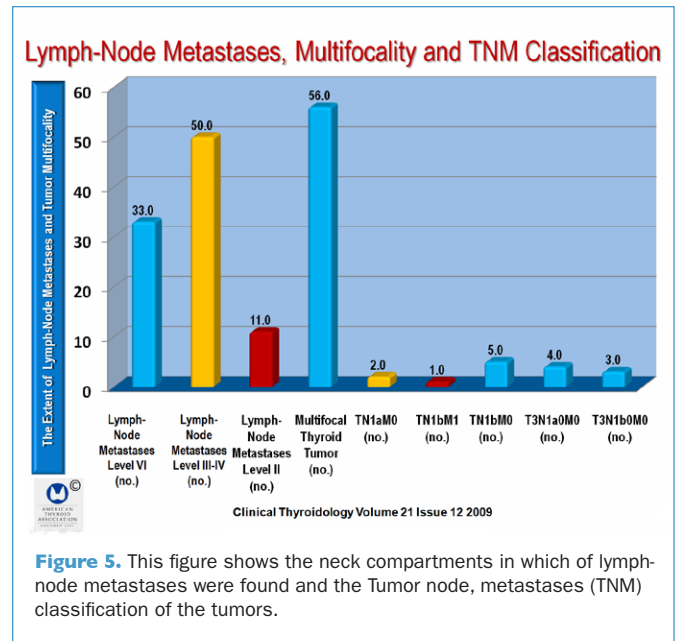


Figure 5. This figure shows the neck compartments in which of lymph-node metastases were found and the Tumor node, metastases (TNM) classification of the tumors.

COMMENTARY

In 2004, I suggested that thyroid cancer occurring in a thyroglossal cyst is a thorny problem that amplifies many of the controversial issues that swirl around the management of small well-differentiated thyroid carcinomas (1). The problem is that thyroglossal cysts are very common, yet they rarely contain tumors. However, when they do, there are myriad diagnostic and therapeutic problems. The diagnostic accuracy of fine-needle aspiration biopsy is low, especially in large cystic lesions with

a small mural tumor. Moreover, thyroglossal-duct remnants are ubiquitous, comprising more than 75% of midline neck tumors in children, and they are even found in about 7% of adults (1). Still, only a very small number of people have thyroglossal-duct cancers. Although some report a higher incidence of thyroid cancers (2), the largest study from California (3) found only 14 thyroid cancers in thyroglossal-duct remnants. Luna-Ortiz and associates (4) found only 215 cases in the world literature in 2004. It is thus not surprising that not many exceptional studies of this problem have been published in the past decade. As a

consequence, the key question remains, "Should thyroidectomy be done when malignant tumor is identified in a thyroglossal-duct remnant?" Another key question that is asked less often is: "Should prophylactic neck compartment dissection be performed in this setting and when if ever should ^{131}I be administered?" (1).

The study by Hartl and associates shines a bright light on this hazy problem. The study is unique insofar as the surgical approach that was taken in this group of 18 patients. Although the Sistrunk procedure was performed on all of the 18 patients, 15 (83%) also had total thyroidectomy as a secondary procedure, and 1 had an isthmusectomy in addition to the Sistrunk procedure, and two had only a Sistrunk procedure. In addition, prophylactic neck dissection in the central compartment with or without lateral-compartment dissection was performed in 16 patients (89%) as part of a surgical protocol used by the authors to optimize tumor staging to facilitate selection of patients for ^{131}I therapy. As a consequence, tumor foci were found in the thyroid in 9 of the 16 patients (56%) who had a total thyroidectomy or in one case, isthmusectomy. In addition to tumor in the thyroglossal-duct remnant, 3 of the 16 patients (19%) were found to have bilateral tumor foci. Lymph-node metastases were found in 12 of the 16 patients (75%) who had prophylactic neck dissections. Lymph-node metastases were found in 6 of 15 central compartment (level VI) dissections (40%) and in 9 of 15 lateral neck dissections (60%). Furthermore, lateral lymph-node metastases were bilateral in 4 patients, on the left side only in 3 patients and on the right side only in 2 patients. A striking finding was skip metastases to the lateral compartments (levels III and IV), without central compartment metastases, which were found in 6 of 15 patients (40%), which is a much higher than the usual rate of skip metastases, which was approximately 20% in several large studies (5;6). Also, level II (subdiaphragmatic) lymph nodes were positive in two patients, one of whom had only two isolated level II lymph-node, and the other had levels III and IV lymph-node metastases. Of the 12 patients with lymph-node metastases, 6 (50%) also had tumor foci in the thyroid gland and the other 50% had no thyroid tumors.

A total of 12 patients (67%) were treated with 100 mCi or more of ^{131}I , 11 of whom (92%) had multifocal thyroid tumors with or without lymph-node metastases, and 8 of the 18 patients (44%) were treated with ^{131}I on the basis of lymph-node metastases found as a result of tumors being upstaged to N1a or N1b after prophylactic neck dissection.

Unlike most studies of thyroglossal-duct cancers, the average follow-up was 11 years, with a median of 12 years and a range of 1 to 22. None were lost to follow-up and no patient had physical evidence of persistent or recurrent disease. All had negative neck ultrasonography and 11 of the 18 patients (61%) had thyrotropin-stimulated serum thyroglobulin measurements,

10 of whom had levels $<1 \mu\text{g/L}$. Of importance, none of the patients had either temporary or permanent recurrent laryngeal-nerve paralysis or hypoparathyroidism.

The findings of this study are very similar to those by Bonnet and associates, also from the Institut Gustave Roussy, Villejuif (7), in which 115 patients with 10- to 20-mm papillary thyroid cancers, all of whom had negative preoperative neck ultrasonography, had prophylactic central- and lateral-compartment lymph-node dissection. The aim of the study by Bonnet, as in the present study, was to determine the effect of lymph-node staging on the indication for ^{131}I treatment. In that study, 42% of the patients with tumors $<20 \text{ mm}$ without lymph-node metastases were not treated with ^{131}I . On the other hand, 58% were treated with ^{131}I because they had lymph-node metastasis, extracapsular thyroid tumor invasion, or an unfavorable histologic subtype. Similar to the Hartl study, after 1 year the neck ultrasonography was normal in all patients, and recombinant human TSH-stimulated thyroglobulin was undetectable for 97% of the patients.

Thus, both studies from the same group in Paris found that precise lymph-node staging by prophylactic neck dissection for tumors initially staged T1N0 modified the indication for ^{131}I ablation in 30% of the patients in the Bonnet study and over twice as many patients (67%) with thyroglossal-duct papillary cancers in the Hartel study.

Hartl and associates point out that prophylactic neck dissection is controversial but that routine central-compartment (level VI) dissection allows staging of the extent of the disease in lymph nodes and is performed by many surgeons to reduce the incidence of reoperation in this region. They also note that prophylactic lateral neck dissection is not part of the current management guidelines for differentiated thyroid cancer.


I thought the Bonnet study was one of the most important studies reported in 2009 (8) and find the present study to be just as important. Hartl and associates reach the conclusion that "Because the rationale for total versus less-than-total thyroidectomy and for elective neck dissection mirrors that for papillary carcinoma arising in the thyroid lobes, we believe that current guidelines for treatment of differentiated thyroid cancer should be followed in treating papillary thyroid cancer arising in thyroglossal duct remnants." This is a well-reasoned conclusion based on important studies that will help further focus the debate over the routine use of prophylactic lymph-node compartment dissection and will facilitate the selection of ^{131}I therapy only in patients with metastases. It perhaps goes without saying that lymph-node level VI compartment dissections must be performed by well trained and highly experienced surgeons as those in the Institut Gustave Roussy

Ernest L. Mazzaferri, MD, MACP

References

1. Mazzaferri E.L. Thyroid cancer in thyroglossal duct remnants: a diagnostic and therapeutic dilemma. *Thyroid* 2004;14:335-6.
2. Tew S, Reeve TS, Poole AG et al. Papillary thyroid carcinoma arising in thyroglossal duct cysts: incidence and management. *Aust N Z J Surg* 1995;65:717-8.
3. Doshi SV, Cruz RM, Hilsinger RL, Jr. Thyroglossal duct carcinoma: a large case series. *Ann Otol Rhinol Laryngol* 2001;110:734-8.
4. Luna-Ortiz K, Hurtado-Lopez LM, Valderrama-Landaeta JL et al. Thyroglossal duct cyst with papillary carcinoma: what must be done? *Thyroid* 2004;14:363-6.
5. Machens A, Holzhausen HJ, Dralle H. Skip metastases in thyroid cancer leaping the central lymph node compartment. *Arch Surg* 2004;139:43-5.
6. Mirallie E, Visset J, Sagan C et al. Localization of cervical node metastasis of papillary thyroid carcinoma. *World J Surg* 1999;23:970-3.
7. Bonnet S, Hartl D, Leboulleux S et al. Prophylactic lymph node dissection for papillary thyroid cancer less than 2 cm: implications for radioiodine treatment. *J Clin Endocrinol Metab* 2009;94:1162-7.
8. Mazzaferri EL. A vision for the surgical management of papillary thyroid carcinoma: extensive lymph node compartmental dissections and selective use of radioiodine. *J Clin Endocrinol Metab* 2009;94:1086-8.

DEDICATED TO SCIENTIFIC INQUIRY, CLINICAL EXCELLENCE, PUBLIC SERVICE, EDUCATION, AND COLLABORATION.



AMERICAN THYROID ASSOCIATION
FOUNDED 1923

ATA Publications Public & Patients Physicians & Professionals

ABOUT THE ATA GIVE ONLINE JOIN THE ATA FELLOWS' CORNER MEMBERS ONLY

JOIN THE AMERICAN THYROID ASSOCIATION

Are you intrigued by the study of the thyroid? **You belong in the ATA!**

ATA members are leaders in thyroidology who promote excellence and innovation in clinical care, research, education, and public policy.

Join us as we advance our understanding of the causes and improve the clinical management of thyroid diseases in this era of rapid pace biomedical discovery.

A close-knit, collegial group of physicians and scientists, the ATA is dedicated to the research and treatment of thyroid diseases. ATA's rich history dates back to 1923 and its members are respected worldwide as leaders in thyroidology.

The ATA encourages you to apply for membership. We want you to experience the wealth of knowledge and enjoy the benefits of being active in this highly specialized and regarded society. The ATA looks forward to having you as a member!

<http://www.thyroid.org/professionals/join/index.html>